

# Safety and Predictive Factors of Short-Term Efficacy of a Single Injection of Mannitol-Modified Cross-Linked Hyaluronic Acid in Patients with Trapeziometacarpal Osteoarthritis. Results of a Multicentre Prospective Open-Label Pilot Study (INSTINCT Trial)

Clinical Medicine Insights: Arthritis and Musculoskeletal Disorders  
Volume 11: 1–7  
© The Author(s) 2018  
Reprints and permissions:  
sagepub.co.uk/journalsPermissions.nav  
DOI: 10.1177/1179544118782901



Jérémy Dauvissat<sup>1</sup>, Christophe Rizzo<sup>2</sup>, Henri Lellouche<sup>3</sup>, Jérôme Porterie<sup>4</sup>, Sylvie Melac-Ducamp<sup>5</sup>, Vincent Locquet<sup>6</sup>, Vincent Travers<sup>7</sup>, Bernard Maillet<sup>8</sup> and Thierry Conrozier<sup>1</sup>

<sup>1</sup>Service de Rhumatologie, Hôpital Nord Franche-Comté, Belfort, France. <sup>2</sup>Clinique du Parc Lyon, Lyon, France. <sup>3</sup>Institut de L'appareil Locomoteur Nollet, Paris, France. <sup>4</sup>Service d'Orthopédie du membre supérieur, Cabinet de Rhumatologie, Auch, France. <sup>5</sup>Cabinet de Rhumatologie, Nevers, France. <sup>6</sup>Institut Chirurgical de la Main et du Membre Supérieur, Villeurbanne, France. <sup>7</sup>Clinique Saint-Charles, Lyon, France. <sup>8</sup>Service de Rhumatologie, Polyclinique Saint-Odilon, Moulins, France.

## ABSTRACT

**PURPOSE:** To assess safety and search predictive factors of efficacy of a single intra-articular injection of a mannitol-modified hyaluronic acid (HA) viscosupplement, in patients having trapeziometacarpal (TMC) osteoarthritis (OA).

**METHODS:** Patients with symptomatic TMC OA, not adequately relieved by analgesic therapy and/or by the use of a thumb splint, were included in a 3-month prospective multicentre open-label trial. All underwent plain radiographs with the Kapandji incidences allowing the Dell radiological grade assessment (1-4). Primary end point was the variation between injection (D0) and day 90 (D90) of the thumb pain (11-point Likert scale). Treatment consisted in a single injection of 0.6 to 1 mL of a viscosupplement made of a cross-linked HA combined with mannitol. All injections were performed under imaging guidance. Predictive factors of pain decrease were studied in univariate and multivariate analysis.

**RESULTS:** A total of 122 patients (76% women, mean age 60, mean disease duration 36 months) were included and 120 (98%) were assessed at 3 months. The TMC OA was of Dell's grade 1, 2, 3, and 4 in 23%, 36.8%, 36.8%, and 3.5% of cases, respectively. At D0, the average (SD) pain level was  $6.5 \pm 1.6$  without significant difference between Dell groups ( $P = .21$ ). At day 90, pain decreased from  $6.5 \pm 1.6$  to  $3.9 \pm 2.5$  (difference  $-2.7 \pm 2.5$ ;  $-42\%$ ;  $P < .0001$ ) without significant difference between Dell grade ( $P = .055$ ), despite a seemingly smaller number of responders in stage 2 patients. The average analgesic consumption decreased in more than 1 out of 2 patients. In multivariate analysis, no predictor of response was identified. There was no safety issue. All adverse events (11%) were transient increase in pain during or following HA administration and resolved without sequel within 1 to 7 days.

**CONCLUSIONS:** This study suggests that a single course of HANOX-M-XL injection is effective in relieving pain in patients with TMC OA, without safety concern. Patients with advanced stage of OA benefit the treatment as much as those with mild or moderate OA.

**KEYWORDS:** Thumb, trapezio-metacarpal joint, viscosupplementation, hyaluronic acid, osteoarthritis

**RECEIVED:** January 24, 2018. **ACCEPTED:** May 20, 2018.

**TYPE:** Original Research

**FUNDING:** The author(s) disclosed receipt of the following financial support for the research, authorship, and/or publication of this article: The INSTINCT study was funded by LABRHA SA, 19 Place Tolozan, Lyon, France.

**DECLARATION OF CONFLICTING INTERESTS:** The author(s) declared the following potential conflicts of interest with respect to the research, authorship, and/or publication of

this article: T.C. received fees from Labrha Sas, Sanofi, and Genevrier for scientific consultant services and board member services. H.L. received fees from Sanofi and Genevrier for consultant services. B.M., J.D., J.P., C.R., S.M-D., V.L., and V.T. declared no potential conflicts of interest.

**CORRESPONDING AUTHOR:** Thierry Conrozier, Département de rhumatologie, Hôpital Nord Franche-Comté, 100 route de Moval, CS 10490, Trevenans, 90015 Belfort, France. Email: thierry.conrozier@hnfc.fr; thierry\_conrozier@hotmail.fr

## Introduction

Rhizarthrosis is a degenerative joint disease affecting the trapeziometacarpal (TMC) joint. Its frequency increases dramatically with age with a prevalence reaching 25% in post-menopausal women<sup>1,2</sup> and more than 90% in elderly over 80.<sup>3</sup> Trapeziometacarpal osteoarthritis (OA) is clinically characterized by chronic pain of the thumb base, usually aggravated by movements and improved with rest. Symptoms intensity varies over time and patients may experience intermittent flare-ups, which worsen pain and functional impairment. However, in many cases, TMC OA remains asymptomatic throughout the evolution.<sup>2</sup> In painful cases, the natural history of the disease is

most often characterized by a gradual decrease in pain over several years, associated with thumb *adductus* deformity.<sup>4</sup>

Depending on pain level, the European League Against Rheumatism (EULAR) recommends the use of varied non-pharmacologic measures,<sup>5</sup> including local massage, physiotherapy, exercises, and thumb base splint.<sup>6</sup> In case of insufficient effectiveness of the nonpharmacologic treatments, pharmacologic modalities are recommended. Because of their good risk benefit ratio, topical capsaicin, and nonsteroidal anti-inflammatory drugs (NSAIDs) are prescribed before resorting to systemic analgesics or NSAIDs. Symptomatic slow-acting drugs for OA (SYSADOA),



Creative Commons Non Commercial CC BY-NC: This article is distributed under the terms of the Creative Commons Attribution-NonCommercial 4.0 License (<http://www.creativecommons.org/licenses/by-nc/4.0/>) which permits non-commercial use, reproduction and distribution of the work without

further permission provided the original work is attributed as specified on the SAGE and Open Access pages (<https://us.sagepub.com/en-us/nam/open-access-at-sage>).

**Table 1.** Dell radiographic classification for trapeziometacarpal osteoarthritis.

STAGE	RADIOGRAPHIC FEATURES
1	Joint space narrowing and subchondral sclerosis but no evidence of subluxation or osteophyte formation
2	Increased subchondral sclerosis and joint space narrowing. Formation of osteophyte at the ulnar border of the trapezium. Metacarpal is subluxated less than 1/3 of the diameter of base of trapezium
3	Further loss of joint space. More prominent osteophyte at the ulnar border of the trapezium. The metacarpal is subluxated more than 1/3 of base of the trapezium
4	Total loss of joint space, greater amount of subluxation/dislocation, and the presence of pan-trapezial arthritis

such as glucosamine, chondroitin sulfate, avocado soybean unsaponifiables, diacerein, may be proposed as they provide a symptomatic benefit with a low level of toxicity. Corticosteroid (CS) intra-articular injections (IA) have been demonstrated to be effective<sup>7</sup> and are recommended in OA flares. Surgical treatment (ie, trapeziectomy with or without interposition, arthrodesis, arthroplasty) is sometimes necessary in patients who remain symptomatic despite appropriate medical treatment or in advanced stages, when conservative treatments are no longer effective.<sup>8,9</sup> However, as the natural evolution of the disease is often favorable, the development of symptomatic treatments, which can bring relief during the most painful period, is particularly necessary.<sup>10</sup> Among the latter, viscosupplementation consists in IA injections of a solution of high-molecular-weight hyaluronic acid (HA) aimed to relieve pain and improve joint function.<sup>11-13</sup> The IA HA injections are recommended by many scientific societies as an adjunctive treatment for knee OA, after failure of first-line treatments,<sup>14</sup> although its usefulness has not been yet unanimously accepted.<sup>15</sup> Viscosupplementation effectiveness has mainly been demonstrated in the early stages of knee<sup>16,17</sup> and hip OA.<sup>18</sup> However, viscosupplementation cannot be considered as a viable alternative to surgical treatment in advanced disease.<sup>14,19</sup> In the treatment of TMC OA, the efficacy and safety of viscosupplementation has been studied in several open-label and randomized controlled trials (RCTs) versus placebo and/or intra-articular corticosteroid (IACS).<sup>20-28</sup> Both IA HA and CS have a similar effectiveness on pain. However, IA HA has been suggested to have a longest duration of effect and to be more efficacious to improve joint function than IACS.<sup>19,23-25,28</sup> However, the data interpretation is limited by the heterogeneity of the trials.<sup>24,25</sup> This heterogeneity is due to (1) variable dosing regimen (number of injections ranging from 1 to 5), (2) different characteristics of the viscosupplements (molecular weight, concentration, linear, or cross-linked structure), (3) injections performed under imaging or landmarks guidance, (4) variable anatomical severity. The required number of injections depends on HA structure (linear

or cross-linked) but not on the joint to be treated.<sup>29,30</sup> It has never been demonstrated that linear HAs can be effective through a single injection regimen.<sup>13,29-31</sup> This is due to the very short half-life<sup>32</sup> of the linear HA molecule, which needs repeated injections.<sup>33,34</sup> Cross-linked HA, whose IA residence time is much longer<sup>35</sup> can require only one injection.<sup>36,37</sup> Another crucial point which can explain discrepancies between studies is the lack of systematic imaging guidance for IA injection. Trapeziometacarpal is a small-sized joint and HA injections must be guided by imaging (ultrasound or fluoroscopy) to ensure a strict IA injection.<sup>13,38,39</sup> Finally, the meta-analyses do not take into account the anatomical severity of TMC OA, which was not always specified in RCTs. When it was, the radiological classification<sup>40-42</sup> and/or incidences<sup>43</sup> were rarely or correctly detailed.

The main objective of the present research was to investigate whether the radiological stage of TMC OA, according to Dell classification<sup>42</sup> (Table 1), could influence the effectiveness of viscosupplementation. The secondary objective was to look for other predictive factors of effectiveness or failure.

## Patients and Methods

### Study population

This study was an observational, single-arm, prospective multi-centre open-label clinical trial, with a 3-month follow-up. To look for predictors of success or failure of viscosupplementation, the inclusion criteria were limited so that the recruited population was as representative as possible of that encountered in daily practice. The decision to make viscosupplementation was taken by experienced specialists in hand OA, in accordance with the current practice and in line with the EULAR recommendations.<sup>5</sup> Patients with symptomatic TMC OA, not sufficiently relieved by conventional first-line treatments (analgesics and/or NSAIDs and/or thumb splint), were included in the study. All underwent X-rays performed according to the Kapandji incidences showing evidence of rhizarthrosis (joint space narrowing and/or osteophyte). Exclusion criteria were scapho-trapeziometacarpal OA, microcrystalline or inflammatory arthritis, viscosupplementation within the last 3 months, IACS during the last previous month, planned surgery during the 3 months of follow-up, and patients unable to give their own informed consent.

### Regulatory

Patients were recruited between March 2016 and February 2017. The study has been registered with the French Agence Nationale de Sécurité du Médicament (ANSM) under the name INSTINCT trial (INfluence of the radiological STAge on efficacy of a single HA INjection in patients with meta-Carpo-Trapezial OA; EudraCT N° 2015-AO1874-45). It received the approval of the Comité Consultatif sur le Traitement de l'Information en matière de Recherche dans le

domaine de la Santé (CCTIRS) and of the Commission Nationale de l'Informatique et des Libertés (CNIL) after the Ethics Committee of Lyon Southeast IV gave its advisory opinion. The study has been conducted in accordance with the Good Clinical Practice and the Ethical Standards of the Declaration of Helsinki. Before enrollment, patients were required to give an informed consent and were free to withdraw at any time for any reason. The patient informed consent form and the protocol, which complied with the requirements of the International Conference on Harmonisation (ICH), were reviewed and approved by the CCTIRS.

### Intervention

All patients received a single-guided IA injection of HANOX-M-XL (HappyMini; LABRHA Laboratory, Lyon, France), in the TMC joint. HANOX-M-XL has been specifically designed for small joints viscosupplementation. Its small volume (1 mL), its high concentration of HA (16 mg/mL), its cross-linked structure, as well as the addition of 35 mg/mL of mannitol (which delays the in situ degradation of HA)<sup>44</sup> allow a single injection dosing regimen.

To ensure the correct IA administration, injection of the viscosupplement (0.6-1 mL according to the immediate tolerability) was performed under ultrasound or radiological guidance, according to the choice and experience of the investigators.

### Evaluation

During the screening visit, after handing a document providing key information about the study, the investigator obtained the patient's consent to participate. Then, he collected demographic data (age, sex, weight, height), pathological data (symptoms duration, bilaterality, previous and current treatments for thumb OA, concomitant therapies for comorbidities), patient self-assessment of pain measured on an 11-point numerical rating scale (0-10NS), and radiological features (Dell stage 1-4). At the end of the visit, the investigator had to plan the HA IA injection within 15 days and chose the type of guidance which will be used (fluoroscopy or ultrasound guidance).

At the last study visit, 3 months later, the investigator obtained the patient self-assessment of pain on 0-10NS, the patient perception of the treatment efficacy using a 4 point NS (0 meaning not effective, 1 slightly effective, 2 effective, and 3 very effective), the variation in analgesic intake (in percentage comparing with the consumption before the injection), and the occurrence of any adverse event (AE).

The primary end point was the pain variation between the injection day (D0) and month 3 (D90). The secondary outcome measures were the patient perception of treatment efficacy and the variation in the use of painkillers.

### Statistics

In this observational study, the number of participants could not be determined a priori. So, the minimum number of patients to be included was set at 100 by a committee of experts specialized in the field, to take into account the multiple potential predictive factors to be analyzed.<sup>17</sup> Predictors of efficacy (demographic, clinical, pathological, radiographic, and therapeutic) were studied using univariate and multivariate analysis from the intent-to-treat population by replacing the missing data using the Last Observation Carried Forward (LOCF) approach. The regression coefficients of the multivariate models (analysis of covariance and mixed model) were considered significant if they were less than 5%. The statistical analysis was performed using Xlstat software © 2017, Addinsoft, Paris, France).

### Results

A total of 122 patients were included and 120 (98%) were assessed at 3 months. In all, 93 participants (76%) were women, the average age was 60 years, and the average disease duration was 36 months. A clinically detectable subluxation of the first metacarpus was found in 66% of cases. The disease was bilateral in 74% of patients. A thumb resting splint was used by 61% of patients, 51% were regular analgesics consumers, 28% and 17% were taking NSAIDs and SYSADOA for OA, respectively. About 21% had received at least one CS IA injection and 7% had previously been treated with viscosupplementation. From a radiological perspective, 23% of the TMC OA were grade 1 according to Dell classification, 36.8% grade 2, 36.8% grade 3, and 3.5% grade 4. The injection was performed using fluoroscopy in 83% and by ultrasound in 17% of cases. The characteristics of the patients at baseline are summarized in Table 2.

At D0, the average (SD) pain level was  $6.5 \pm 1.6$ . In all, 13 patients (10.7%) reached the Patient-Acceptable Symptom State (PASS) threshold.<sup>29</sup> At inclusion, mean (SD) pain was  $6.3 \pm 1.6$  in patients with Dell 1,  $6.5 \pm 1.4$  in patients with Dell 2, and  $6.6 \pm 1.7$  in patients with Dell 3. It was slightly higher  $7.3 \pm 3.0$  in patients with Dell 4, but the difference did not reach the statistical significance ( $P = .33$ ). When pooling the Dell stages 1+2 and 3+4, the mean pain was  $6.4 \pm 1.5$  and  $6.6 \pm 1.8$ , respectively, without significant difference between groups ( $P = .21$ ). Similarly, there was no statistically significant correlation between the Dell grade and the date of onset of symptoms ( $P = .15$ ).

At day 90, the average pain decreased significantly from  $6.5 \pm 1.6$  to  $3.9 \pm 2.5$  ( $P < .0001$ ). The mean pain improvement, regardless the radiological stage, was  $-2.7 \pm 2.5$  (-42%). It was much higher than the Minimal Clinically Important Improvement (MCII)<sup>45</sup>, defined by an absolute decrease of -1.6 and a relative change of -23%.<sup>46</sup> In all, 69 patients (57.5%) reached the PASS criteria<sup>29</sup> (Figure 1). According to Dell stage, pain was  $3.7 \pm 2.5$  in Dell 1,  $4.5 \pm 2.3$  in Dell 2,  $3.7 \pm 2.6$  in Dell 3,

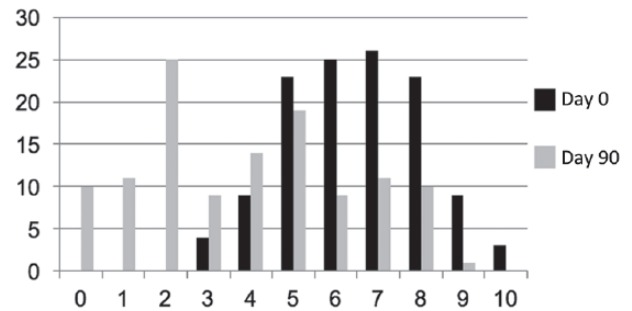
**Table 2.** Characteristics of patients at inclusion (N= 122).

CHARACTERISTICS	%	CHARACTERISTICS	%
Age, y		Dell grade	
41–50	12	1	23
51–60	35	2	37
61–70	33	3	37
71–80	13	4	3
Sex		Analgesics	
Male	24	Yes	51
Female	76	No	49
BMI, kg/m <sup>2</sup>		NSAIDs	
<25	45	Yes	28
25–30	34	No	72
30–35	21		
Rhizarthrosis		SYSADOAs	
Unilateral	36	Yes	17
Bilateral	64	No	83
Target thumb		Splint	
Right	50	Yes	61
Left	50	No	39
Disease duration, mo		Previous intra-articular injection	
0–12	31	Steroids	
12–24	17	Yes	21
24–60	33	No	79
>60	19	Hyaluronic acid	
		Yes	7
		No	93
TMC clinically detectable subluxation		Imaging guidance	
Yes	66	Ultrasound	17
No	34	Fluoroscopy	83

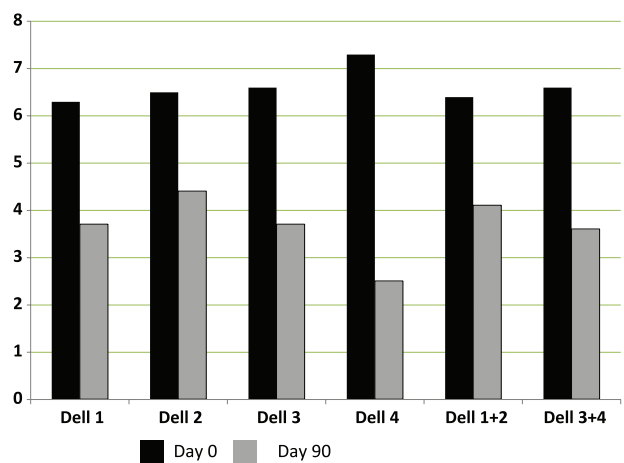
Abbreviations: BMI, body mass index; NSAIDs, nonsteroidal anti-inflammatory drugs; SYSADOA, symptomatic slow-acting drugs for OA; TMC, trapeziometacarpal.

$2.5 \pm 3.8$  in Dell 4. There was no significant difference between groups ( $P = .50$ ). In Dell grades 1+2 and 3+4, the decrease in pain between day 0 and day 90 was, respectively,  $-2.5 \pm 2.6$  and  $-3.1 \pm 2.7$ , again without significant difference between groups ( $P = .38$ ).

About 69% of patients estimated the treatment as effective (21% very effective, 31% effective, 17% slightly effective) and 21% found it ineffective. Again, there was no significant



**Figure 1.** Number of patients according to pain score categories (numerical rating scale 0-10) at baseline (N= 122) and 3 months after viscosupplementation (N= 120).

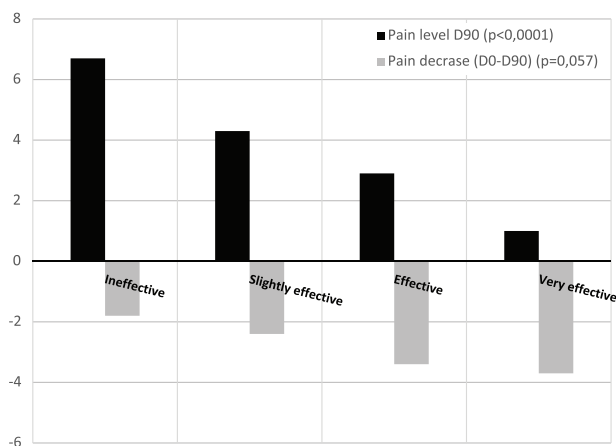


**Figure 2.** Average level of pain (numerical rating scale 0-10) at baseline and 90 days after a single injection of HANOX-M-XL for trapeziometacarpal osteoarthritis according to Dell grade.

difference depending on the Dell grade ( $P = .055$ ), despite a seemingly smaller number of responders in stage 2 patients. Figure 2 clearly illustrates that patients' assessment of efficacy was less related to the decrease in pain between day 0 and day 90 ( $P = .057$ ) than to its level at final evaluation ( $P < .0001$ ). In patients using analgesics or NSAIDs, the average consumption during follow-up decreased in more than 1 out of 2 patients. In 78% of cases, analgesic consumption decreased by more than 50% and in 66% of cases by more than 75%. In univariate analysis, the clinical response was significantly worse in patients taking NSAIDs ( $P = .012$ ), but this difference no longer reached the significance threshold in the multivariate analysis. Finally, the guidance technique did not significantly influence the clinical response ( $P = .16$ ).

Device and/or procedure-related AEs were reported by 11% of patients (14 patients). All AEs reported were an increase in the thumb base pain, which occurred within the very next hours after the injection and lasted a few days. In 8 cases, the pain was estimated severe and in 3 cases moderate. Five patients needed to take complementary analgesic treatment for 3 to 7 days. All AEs have been resolved in 3 to 7 days. The occurrence





**Figure 3.** Pain level at D90 (range 0 to 10) and decrease in pain between D0 and D90 (range -10 to 0) according to the patients' self-rating of effectiveness.

of an AE was not correlated with the final clinical outcome ( $P = .81$ ). No severe AE was reported.

## Discussion

The main information from this study is that, contrary to what is usually observed for the other joints,<sup>17,38,39,47,48</sup> the radiological severity of TMC OA does not have a negative influence on the clinical response to viscosupplementation. Surprisingly, it was in patients with Dell grade 2 that the results tended to be the worst, even if the difference did not reach the threshold of statistical significance. We can hypothesize that, in grade 2, the articular instability and the gradual subluxation of the first metacarpus cause a painful distension of the articular capsule. Indeed, the capsule is very innervated and its distension may cause severe pain. In Dell stage 2, it is likely that pain is mainly of capsulo-ligamentous origin and therefore may not be very sensitive to viscosupplementation. On the contrary, in the more advanced stages, the joint is less unstable because of the presence of osteophytes. Therefore, it might be hypothesized that the pain would mainly come from the degenerative lesions and viscosupplementation would be more effective. This hypothesis would corroborate the fact that TMC OA is often more painful at early stages than in more advanced stages, when joint deformities are fixed.

The present single-arm study was not designed to demonstrate the efficacy of HANOX-M-XL but to search for possible predictors of success or failure. Therefore, no formal conclusions can be made about the real effectiveness of the treatment. Nevertheless, its efficacy is strongly suggested by the very significant reduction in pain at day 90 compared with that reported at day 0, by the very positive patients' perception of the efficacy (2 out of 3 patients have reported improvement) and by the significant decrease in the analgesics/NSAIDs consumption. Above all, the magnitude of improvement, in both absolute value and percentage, greatly exceeded the threshold

that defines MCII, indicating the clinical relevance of this improvement.<sup>46</sup>

These results are consistent with those of the literature,<sup>19,24,26,49</sup> but while most of results in other studies were obtained with 2 or 3 HA injections,<sup>19,24,26,50</sup> ours were obtained after a single injection. Such a protocol was possible because of the cross-linked structure of HANOX-M-XL. In a recent study, in patients with Eaton-Littler stage 2 and 3 TMC OA, Velasco et al.<sup>51</sup> demonstrated a decrease in pain of  $-1.9 \pm 1.9$  mm ( $-28\%$ ) on the 10-mm visual analog scale, after a single injection of 1 mL of NASHA (nonanimal hyaluronic acid), a cross-linked viscosupplement also designed for single-shot injection. Although no conclusions can be drawn in the absence of a comparative study, we can notice that, in our work, the average decrease in pain at 3 months ( $-2.7 \pm 2.5$  and  $-42\%$ ) was more substantial. Another interesting clinical finding is that patients' evaluation of efficacy was less related to the decrease in pain over time than to pain level at the time of final evaluation. This confirms, as previously showed<sup>52,53</sup> that in the patient's feeling (Figure 3), getting "well" is more important than getting "better." This also suggests that the variation of pain over time, whether in absolute value or in percentage, is probably not the best criterion for evaluating the effectiveness of viscosupplementation because it strongly depends on the level of pain at baseline.<sup>52,54</sup> In addition, this study provided interesting data concerning the safety of TMC viscosupplementation. The overall tolerability was good, similar to that reported in the literature with noncross-linked and non-mannitol-modified HAs.<sup>24,25,27,55</sup> Nevertheless, it seems important to us to carefully inform patients of the significant frequency of postinjection pain, which may last up to a week and possibly require a symptomatic treatment.

The main strength of this study is that it was conducted on the largest cohort ever published in TMC OA viscosupplementation. Moreover, the recruitment by both rheumatologists and orthopedic surgeons, as well as the lack of inclusion/exclusion criteria related to clinical or anatomical severity, allowed to get as close as possible to the daily clinical practice: predominance of postmenopausal women, diversity of radiological stages, very large range of pain level (3 to 10/10) at inclusion. Finally, the protocol required systematically image-guided injections to ensure the accurate IA HA administration, precaution which was not taken in most of published clinical trials.<sup>19,20,24,26,50</sup>

This work suffers also from some weaknesses. The 3-month follow-up is appropriate to evaluate the predictors of short-term success but is probably insufficient to assert efficacy is lasting in the advanced anatomical stages as much as in the early stages. It is also possible that the results might have been slightly different if we had used another radiological classification. In addition, an ultrasound examination performed before enrollment might have been able to detect a possible flare-up with synovial effusion in some subjects. In such patients, IACS would have been more appropriate than viscosupplementation.

Finally, no functional score, such as AUSCAN score,<sup>56</sup> Dreiser index,<sup>57</sup> or Cochin score,<sup>58</sup> was used to evaluate the level of disability and the clinical response to viscosupplementation. Thus, our data cannot prove that viscosupplementation has a positive effect on function, as has been suggested in a recent meta-analysis.<sup>24</sup>

## Conclusions

This prospective study on the largest cohort ever published in rhizarthrosis viscosupplementation showed that a single injection of 0.6 to 1 mL of HANOX-M-XL, performed under imaging guidance, significantly improves pain for at least 3 months, regardless the degree of subluxation of the TMC joint. This suggests that, unlike in other joints, viscosupplementation may be proposed in advanced anatomical forms of TMC OA. However, viscosupplementation remains a palliative treatment of TMC OA and does not be considered as a substitute for surgery, especially in patients with severe disability. Finally, although the overall tolerability of HA injection was good, it seems to us necessary to carefully inform patients regarding the risk of pain recrudescence the very next days following injection. Further studies, with longer follow-up, are needed to confirm these results.

## Acknowledgements

Data from the INSTINCT trial are accessible at Laboratoire de Rhumatologie Appliquée, 19 Place Tolozan, F-69001 Lyon, France.

## Author Contributions

JD analyzed the data and wrote the manuscript. TC participated in the design of the study, was the national coordinator of the trial and participated to the writing the manuscript. HL, JP, CR, SM-D, VL, VT, and BM were clinical investigators of the trial, participated in collecting clinical data and writing of the manuscript. All authors read, commented, made changes, and then approved the final manuscript.

## REFERENCES

- Sarax A, Le Nen D. Arthrose de la main et du poignet. *Elev Masson*. 2009;4:1-10.
- Jonsson H. Age related prevalence of hand osteoarthritis diagnosed by photography (HOAScore). *BMC Musculoskelet Disord*. 2017;18:508. doi:10.1186/s12891-017-1870-0.
- Sodha S, Ring D, Zurakowski D, Jupiter JB. Prevalence of osteoarthritis of the trapeziometacarpal joint. *J Bone Joint Surg Am*. 2005;87:2614-2618.
- Chevalier X, Compaore C, Eymard F, Flipo RM. Rhizarthrose. *Rev Rhum Monogr*. 2012;79:110-115.
- Zhang W, Doherty M, Leeb BF, et al. EULAR evidence based recommendations for the management of hand osteoarthritis: report of a Task Force of the EULAR Standing Committee for International Clinical Studies Including Therapeutics (ESCISt). *Ann Rheum Dis*. 2007;66:377-388.
- Rannou F, Dimet J, Boutron I, et al. Splint for base-of-thumb osteoarthritis: a randomized trial. *Ann Intern Med*. 2009;150:661-669.
- Fowler A, Swindells MG, Burke FD. Intra-articular corticosteroid injections to manage trapeziometacarpal osteoarthritis—a systematic review. *Hand (N Y)*. 2015;10:583-592.
- Gay A-M, Cerlier A, Iniesta A, Legré R. Surgery for trapeziometacarpal osteoarthritis. *Hand Surg Rehabil*. 2016;35:238-249.
- Vermeulen GM, Slijper H, Feitz R, Hovius SER, Moojen TM, Selles RW. Surgical management of primary thumb carpometacarpal osteoarthritis: a systematic review. *J Hand Surg*. 2011;36:157-169.
- Yao J, Park MJ. Early treatment of degenerative arthritis of the thumb carpometacarpal joint. *Hand Clin*. 2008;24:251-261.
- du Souich P. Absorption, distribution and mechanism of action of SYSADOAS. *Pharmacol Ther*. 2014;142:362-374.
- Balazs EA. Analgesic effect of elastoviscous hyaluronan solutions and the treatment of arthritic pain. *Cells Tissues Organs*. 2003;174:49-62.
- Balazs EA. Viscosupplementation for treatment of osteoarthritis: from initial discovery to current status and results. *Surg Technol Int*. 2004;12:278-289.
- Henrotin Y, Raman R, Richette P, et al. Consensus statement on viscosupplementation with hyaluronic acid for the management of osteoarthritis. *Semin Arthritis Rheum*. 2015;45:140-149.
- Jevsevar DS. Treatment of osteoarthritis of the knee: evidence-based guideline, 2nd edition. *J Am Acad Orthop Surg*. 2013;21:571-576.
- Bruyère O, Cooper C, Pelletier J-P, et al. An algorithm recommendation for the management of knee osteoarthritis in Europe and internationally: a report from a task force of the European Society for Clinical and Economic Aspects of Osteoporosis and Osteoarthritis (ESCEO). *Semin Arthritis Rheum*. 2014;44:253-263.
- Bannuru RR, Schmid CH, Kent DM, Vaysbrot EE, Wong JB, McAlindon TE. Comparative effectiveness of pharmacologic interventions for knee osteoarthritis: a systematic review and network meta-analysis. *Ann Intern Med*. 2015;162:46-54.
- Eymard F, Maillet B, Lellouche H, et al. Predictors of response to viscosupplementation in patients with hip osteoarthritis: results of a prospective, observational, multicentre, open-label, pilot study. *BMC Musculoskelet Disord*. 2017;18:3. doi:10.1186/s12891-016-1359-2.
- Conrozier T, Bossert M, Walliser-Lohse A, Sondag M, Balblanc JC. Viscosupplementation with HANOX-M-XL is effective in moderate hip osteoarthritis but is not an alternative to hip joint surgery in patients with severe disease. Results of a clinical survey in 191 patients treated in daily practice. *Eur J Musculoskelet Dis*. 2014;2:49-55.
- Heyworth BE, Lee JH, Kim PD, Lipton CB, Strauch RJ, Rosenwasser MP. Hyalan versus corticosteroid versus placebo for treatment of basal joint arthritis: a prospective, randomized, double-blinded clinical trial. *J Hand Surg*. 2008;33:40-48.
- Tenti S, Pascarelli NA, Giannotti S, Galeazzi M, Giordano N, Fioravanti A. Can hybrid hyaluronic acid represent a valid approach to treat rizoarthrosis? A retrospective comparative study. *BMC Musculoskelet Disord*. 2017;18:444. doi:10.1186/s12891-017-1809-5.
- Stahl S, Karsh-Zafir I, Ratzon N, Rosenberg N. Comparison of intraarticular injection of depot corticosteroid and hyaluronic acid for treatment of degenerative trapeziometacarpal joints. *J Clin Rheumatol*. 2005;11:299-302.
- Bahadir C, Onal B, Dayan VY, Güler N. Comparison of therapeutic effects of sodium hyaluronate and corticosteroid injections on trapeziometacarpal joint osteoarthritis. *Clin Rheumatol*. 2009;28:529-533.
- Trellu S, Dadoun S, Berenbaum F, Fautrel B, Gossec L. Intra-articular injections in thumb osteoarthritis: a systematic review and meta-analysis of randomized controlled trials. *J Bone Spine Rev Rhum*. 2015;82:315-319.
- He W-W, Kuang M-J, Zhao J, et al. Efficacy and safety of intraarticular hyaluronic acid and corticosteroid for knee osteoarthritis: a meta-analysis. *Int J Surg Lond Engl*. 2017;39:95-103.
- Maheu E, Rannou F, Reginster J-Y. Efficacy and safety of hyaluronic acid in the management of osteoarthritis: evidence from real-life setting trials and surveys. *Semin Arthritis Rheum*. 2016;45:S28-S33.
- Figen Ayhan F, Ustün N. The evaluation of efficacy and tolerability of Hyalan G-F 20 in bilateral thumb base osteoarthritis: 6 months follow-up. *Clin Rheumatol*. 2009;28:535-541.
- Monfort J, Rotés-Sala D, Segalés N, et al. Comparative efficacy of intra-articular hyaluronic acid and corticoid injections in osteoarthritis of the first carpometacarpal joint: results of a 6-month single-masked randomized study. *Joint Bone Spine*. 2015;82:116-121. doi:10.1016/j.jbspin.2014.08.008.
- Conrozier T. Optimizing the effectiveness of viscosupplementation in non-knee osteoarthritis. *Joint Bone Spine*. 2016;83:1-2. doi:10.1016/j.jbspin.2015.08.009.
- Richette P, Ravaud P, Conrozier T, et al. Effect of hyaluronic acid in symptomatic hip osteoarthritis: a multicenter, randomized, placebo-controlled trial. *Arthritis Rheum*. 2009;60:824-830.
- DeGroot H, Uzunishvili S, Weir R, Al-omari A, Gomes B. Intra-articular injection of hyaluronic acid is not superior to saline solution injection for ankle arthritis: a randomized, double-blind, placebo-controlled study. *J Bone Joint Surg Am*. 2012;94:2-8.
- Lindenhayn K, Heilmann HH, Niederhausen T, Walther HU, Pohlentz K. Elimination of tritium-labelled hyaluronic acid from normal and osteoarthritic rabbit knee joints. *Eur J Clin Chem Clin Biochem*. 1997;35:355-363.
- Eyigör C, Pirim A, Eyigör S, Uyar M. Efficacy of intraarticular hyaluronic acid injection through a lateral approach under fluoroscopic control for advanced hip osteoarthritis. *Agri*. 2010;22:139-144.

34. Cohen MM, Altman RD, Hollstrom R, Hollstrom C, Sun C, Gipson B. Safety and efficacy of intra-articular sodium hyaluronate (Hyalgan) in a randomized, double-blind study for osteoarthritis of the ankle. *Foot Ankle Int.* 2008;29:657–663.
35. Lindqvist U, Tolmachev V, Kairemo K, Aström G, Jonsson E, Lundqvist H. Elimination of stabilised hyaluronan from the knee joint in healthy men. *Clin Pharmacokinet.* 2002;41:603–613.
36. Conrozier T, Bertin P, Baillieu F, et al. Clinical response to intra-articular injections of hylan G-F 20 in symptomatic hip osteoarthritis: the OMERACT-OARSI criteria applied to the results of a pilot study. *Joint Bone Spine.* 2006;73:705–709.
37. Witteveen AGH, Giannini S, Guido G, et al. A prospective multi-centre, open study of the safety and efficacy of hylan G-F 20 (Synvisc) in patients with symptomatic ankle (talo-crural) osteoarthritis. *Foot Ankle Surg.* 2008;14:145–152.
38. Legré-Boyer V. Viscosupplementation: techniques, indications, results. *Orthop Traumatol Surg Res.* 2015;101:S101–S108. doi:10.1016/j.otsr.2014.07.027.
39. Raman R, Henrotin Y, Chevalier X, et al. Decision algorithms for the retreatment with viscosupplementation in patients suffering from knee osteoarthritis: recommendations from the EUROpean VIScosupplementation COnsensus Group (EUROVISCOSCO) [published online ahead of print February 1, 2017]. *Cartilage.* doi:10.1177/1947603517693043.
40. Spaans AJ, van Laarhoven CM, Schuurman AH, van Minnen LP. Interobserver agreement of the Eaton-Littler classification system and treatment strategy of thumb carpometacarpal joint osteoarthritis. *J Hand Surg.* 2011;36:1467–1470.
41. Comtet JJ, Gazarian A, Fockens W. Definition and classification of basal joint osteoarthritis. A critical analysis and proposals. Treatment options. *Chir Main.* 2001;20:5–10.
42. Dell PC, Brushart TM, Smith RJ. Treatment of trapeziometacarpal arthritis: results of resection arthroplasty. *J Hand Surg.* 1978;3:243–249.
43. Kapandji A, Moatti E, Raab C. La radiographie spécifique de l'articulation trapèze-métacarpienne. *Sa Technique, Son Intérêt.* 1980;34:719–726.
44. Conrozier T, Mathieu P, Rinaudo M. Mannitol preserves the viscoelastic properties of hyaluronic acid in an in vitro model of oxidative stress. *Rheumatol Ther.* 2014;1:45–54.
45. Tubach F, Ravaud P, Martin-Mola E, et al. Minimum clinically important improvement and patient acceptable symptom state in pain and function in rheumatoid arthritis, ankylosing spondylitis, chronic back pain, hand osteoarthritis, and hip and knee osteoarthritis: results from a prospective multina. *Arthritis Care Res.* 2012;64:1699–1707.
46. Bhadra AK, Altman R, Dasa V, et al. Appropriate use criteria for hyaluronic acid in the treatment of knee osteoarthritis in the United States. *Cartilage.* 2017;8:234–254.
47. Toh EM, Prasad PS, Teanby D. Correlating the efficacy of knee viscosupplementation with osteoarthritic changes on roentgenological examination. *Knee.* 2002;9:321–330.
48. Eymard F, Chevalier X, Conrozier T. Obesity and radiological severity are associated with viscosupplementation failure in patients with knee osteoarthritis. *J Orthop Res.* 2017;35:2269–2274.
49. Roux C, Fontas E, Breuil V, Brocq O, Albert C, Euller-Ziegler L. Injection of intra-articular sodium hyaluronidate (Sinovial) into the carpometacarpal joint of the thumb (CMC1) in osteoarthritis. A prospective evaluation of efficacy. *Joint Bone Spine.* 2007;74:368–372.
50. Fuchs S, Mönikes R, Wohlmeiner A, Heyse T. Intra-articular hyaluronic acid compared with corticoid injections for the treatment of rhizarthrosis. *Osteoarthritis Cartilage.* 2006;14:82–88.
51. Velasco E, Ribera MV, Pi J. Single-arm open-label study of Durolane (NASHA nonanimal hyaluronic acid) for the treatment of osteoarthritis of the thumb. *Open Access Rheumatol.* 2017;9:61–66.
52. Conrozier T, Monet M, Lohse A, Raman R. Getting better or getting well? The patient acceptable symptom state (PASS) better predicts patient's satisfaction than the decrease of pain, in knee osteoarthritis subjects treated with viscosupplementation [published online ahead of print August 1, 2017]. *Cartilage.* doi:10.1177/1947603517723072.
53. Perrot S, Bertin P. "Feeling better" or "feeling well" in usual care of hip and knee osteoarthritis pain: determination of cutoff points for patient acceptable symptom state (PASS) and minimal clinically important improvement (MCII) at rest and on movement in a national multicenter cohort study of 2414 patients with painful osteoarthritis. *Pain.* 2013;154:248–256.
54. Bannuru RR, Vaysbrot EE, McIntyre LF. Did the American Academy of Orthopaedic Surgeons osteoarthritis guidelines miss the mark? *Arthroscopy.* 2014;30:86–89. doi:10.1016/j.arthro.2013.10.007.
55. Conrozier T, Couris CM, Mathieu P, et al. Safety, efficacy and predictive factors of efficacy of a single intra-articular injection of non-animal-stabilized-hyaluronic acid in the hip joint: results of a standardized follow-up of patients treated for hip osteoarthritis in daily practice. *Arch Orthop Trauma Surg.* 2009;129:843–848.
56. Allen KD, DeVellis RF, Renner JB, Kraus VB, Jordan JM. Validity and factor structure of the AUSCAN osteoarthritis hand index in a community-based sample. *Osteoarthritis Cartilage.* 2007;15:830–836.
57. Dreiser RL, Maheu E, Guillou GB, Caspard H, Grouin JM. Validation of an algofunctional index for osteoarthritis of the hand. *Rev Rbum Engl Ed.* 1995;62:43S–53S.
58. Poiraudou S, Chevalier X, Conrozier T, et al. Reliability, validity, and sensitivity to change of the Cochin hand functional disability scale in hand osteoarthritis. *Osteoarthritis Cartilage.* 2001;9:570–577.